

CASE REPORT

CUTANEOUS LARVA MIGRANS

Chouhan Chandraprakash¹, Kachhawa Dilip², Rao Pankaj³

1. Assistant Professor, Department of Skin, VD and Leprosy, Dr. S. N. Medical College, Jodhpur, Rajasthan, India

2. Senior professor, Department of Skin, VD and Leprosy, Dr. S. N. Medical College, Jodhpur, Rajasthan, India

3. Assistant Professor, Department of Skin, VD and Leprosy, Dr. S. N. Medical College, Jodhpur, Rajasthan, India

Corresponding Author: Dr Chandraprakash Chouhan , F-46, PRATAP NAGAR JODHPUR.

Mob:- 9887503165. Email:- chandraprakash.chouhan@gmail.com.

ABSTRACT:

Background:

Cutaneous larva migrans may be diagnosed by the typical clinical presentation, consisting on a pruritic serpiginous lesion.

CASE PRESENTATION

52 -year-old man, presented with a 1.5month history of pruritic cutaneous lesions that had not resolved after treatment with oral antihistamines and topical fluocinolone ointment. Physical examination showed a serpiginous, erythematous and slightly elevated lesion of variable length present in between pruritic papulovesicular and eczematous lesions on back and left upper shoulder . Patient affirmed that the lesion advanced progressively. Laboratory analyses only revealed an elevated absolute eosinophil count. Biopsy taken but not significant.

Ivermectin 12mg once weekly was administered to the patient with complete resolution of symptoms within 1 week. Lesions almost completely healed within 1month.

CONCLUSION :

We review clinical, diagnosis and therapeutic options with excellent response to oral ivermectin to cutaneous larva migrans.

Key words:- Serpiginous, Papulovesicular lesions , Eosinophil count

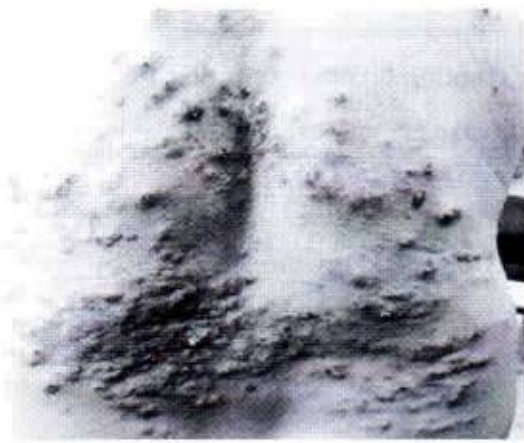


Fig.1. First day

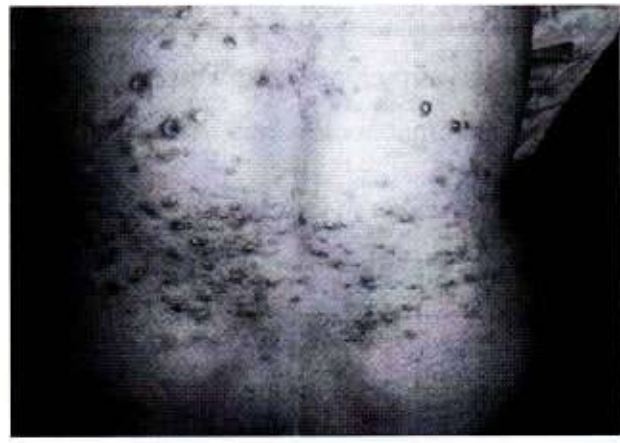

Fig.2. After 7 days

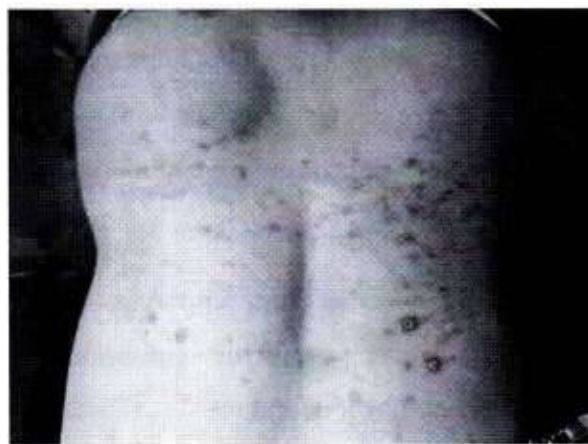

Fig.3. After 28 days

52year old man presented with 1.5 month history of pruritic cutaneous lesions that had not resolved after treatment with oral antihistamines and topical fluocinolone ointment. He had no other symptoms and was otherwise well. His medical history was irrelevant.

Physical examination showed a serpiginous, erythematous and slightly elevated lesion of variable length present in between pruritic papulovesicular and eczematous lesions on back and left upper shoulder (image 1) . Patient affirmed that the lesion advanced progressively. He has taken antihistamines, oral and topical steroid and antibiotic treatment but no improvement in symptoms and cutaneous lesions. The remainder of his physical examination was within normal limits. Laboratory analyses only revealed an elevated absolute eosinophil count ($1534 \times 10^9/L$).

Ivermectin 12mg once weekly was administered to the patient with complete resolution of symptoms within 1 week (image 2). Lesions healed completely within 1month (image3).

DISCUSSION

Cutaneous larva migrans – also known as creeping eruption or sandworm disease – is caused by larvae of animal hookworms. *Ancylostoma braziliense* is the most common offender [1].

The disease is endemic in resource-poor communities in the developing world, particularly in Brazil, India, and the West Indies. Most often, people pick up the infection by walking through contaminated areas barefoot or with open-type shoes, or by sitting in tainted soil or sand [1].

The main affected areas are the dorsum and sole of the feet (uni and bilateral), buttocks, pelvic waist, legs and shoulders. More than one lesion is compatible with more than one entry point. The main signs and symptoms are linear and/or serpiginous lesions (which progress from 2–3 mm to 2–3 cm per day) and the pruritus. This is intensified after some days by the inflammatory reaction of the host and may even interfere with sleep. Systemic signs include peripheral eosinophilia (Loeffler syndrome), migratory pulmonary infiltrates, and increased immunoglobulin E levels, but are rarely seen.

The diagnosis of hookworm-related cutaneous larva migrans is easily made clinically on the basis of typical clinical presentation which is a pruritic serpiginous lesion. Creeping eruption as a clinical sign is diagnostic; a biopsy is not useful.

Even though the condition is self-limited, the intense pruritus and risk for infection mandate treatment. Different therapeutic approaches are effective: a single dose of ivermectin (200 µg per kg bodyweight) kills the migrating larvae effectively and relieves itching quickly. Oral albendazole (400 mg daily), given for 5–7 days, shows excellent cure rates and the drug is well-tolerated by patients [3]. Thiabendazole (50 mg per kg bodyweight for 2–4 days) was widely used after the first report of its efficacy in 1963. However, given orally the substance is poorly tolerated, and frequently causes dizziness, nausea, vomiting, and intestinal cramps [2]. Topical thiabendazole 10% cream, although less effective, is a good alternative for young children to avoid the potential side effects of systemic medications.

The prognosis is excellent. This is a self-limiting disease. Humans are accidental, dead-end hosts, with the larva dying and the lesions resolving within 4–8 weeks, as long as 1 year in rare cases.

In prevention, it is best to wear shoes that completely cover the feet. Also, one should avoid sitting or lying on bare sand, even if on a towel. Deworming of pets is recommended [1]

REFERENCES

1. Prayaga S, Mannepuli GB. A tropical souvenir not worth picking up. *Cleve Clin J Med.* 2006;73:458–459.
2. Heukelbach J, Feldmeier H. Epidemiological and clinical characteristics of hookworm-related cutaneous larva migrans. *Lancet Infect Dis.* 2008;8:302–309.
3. Veraldi S, Rizzitelli G. Effectiveness of a new therapeutic regimen with albendazole in cutaneous larva migrans. *Eur J Dermatol.* 1999;9:352–353.