

CASE REPORT

CARDIAC CEPHALGIA: AN UNCOMMON PRESENTATION OF A COMMON DISEASE

Mathur Rohit

Associate Professor, Department of Cardiology, Dr. S. N. Medical College, Jodhpur, Rajasthan, India

INTRODUCTION

Cardiac cephalgia(CC) is the headache precipitated by ischemic heart disease(IHD). It was first defined as a separate entity in 1997.[1] Classically, angina presents as precordial pain/discomfort with radiation to sites such as left upper limb, back, neck, jaw, and epigastrium. However pain may occur in abnormal sites too. Headache may be the only presentation of coronary artery disease (CAD). The diagnosis relies on the presence of severe headache which gets worsened by physical exercise or stress, and relieved with rest and/or sublingual nitrate administration. We report a case of 51yr old male who presented with new onset exertional headache,and was found to be having severe CAD.

CASE REPORT

A 51 yr old male, a know case of hypertension and type 2 diabetes mellitus(T2DM),with the history of CAD and post stenting to Left Circumflex(LCX) artery and Left anterior descending(LAD) in 2016, presented with the chief complaints of bilateral jaw pain and headache on exertion, restricted to forehead for the past 10 days. Headache used to get relieved by taking sublingual nitrate or rest. Clinical examination, including neurological examination, did not reveal any abnormality. Complete blood counts, blood biochemistry, serum troponin levels were within the normal range. Electrocardiogram(ECG) showed normal sinus rhythm with normal QRS axis.

Patient underwent coronary angiography(CAG) which showed triple vessel disease(TVD) with patent LAD stent and 50% in-stent restenosis(ISR) of LCX stent.[Fig 1] Patient underwent percutaneous transluminal coronary angioplasty(PTCA) to Ramus with 2.5×23 mm drug eluting stent(DES).[Fig 2] Patient experienced relief in his symptoms. Patient had an uneventful course in the hospital and was discharged on dual antiplatelets(DAPT) and statin.

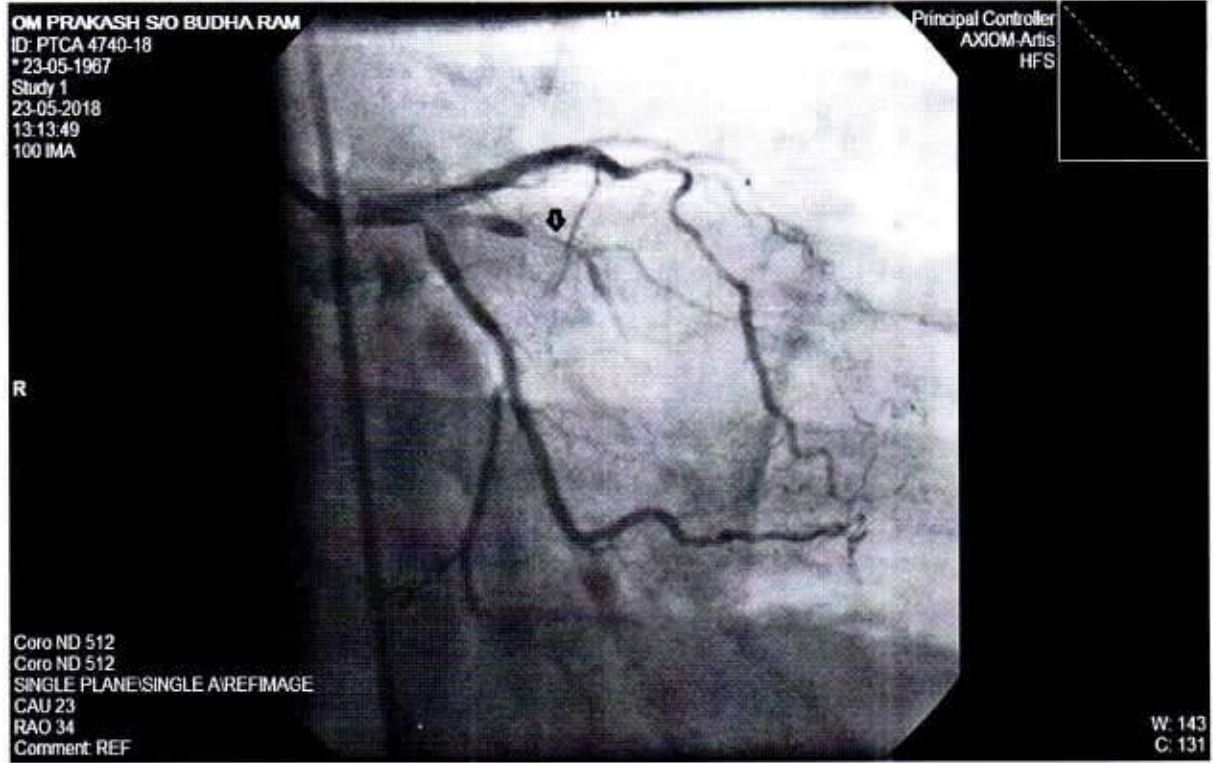


Fig 1: CAG showing patent LAD stent and LCX ISR with Ramus Intermedius showing mid 95% lesion (arrow)

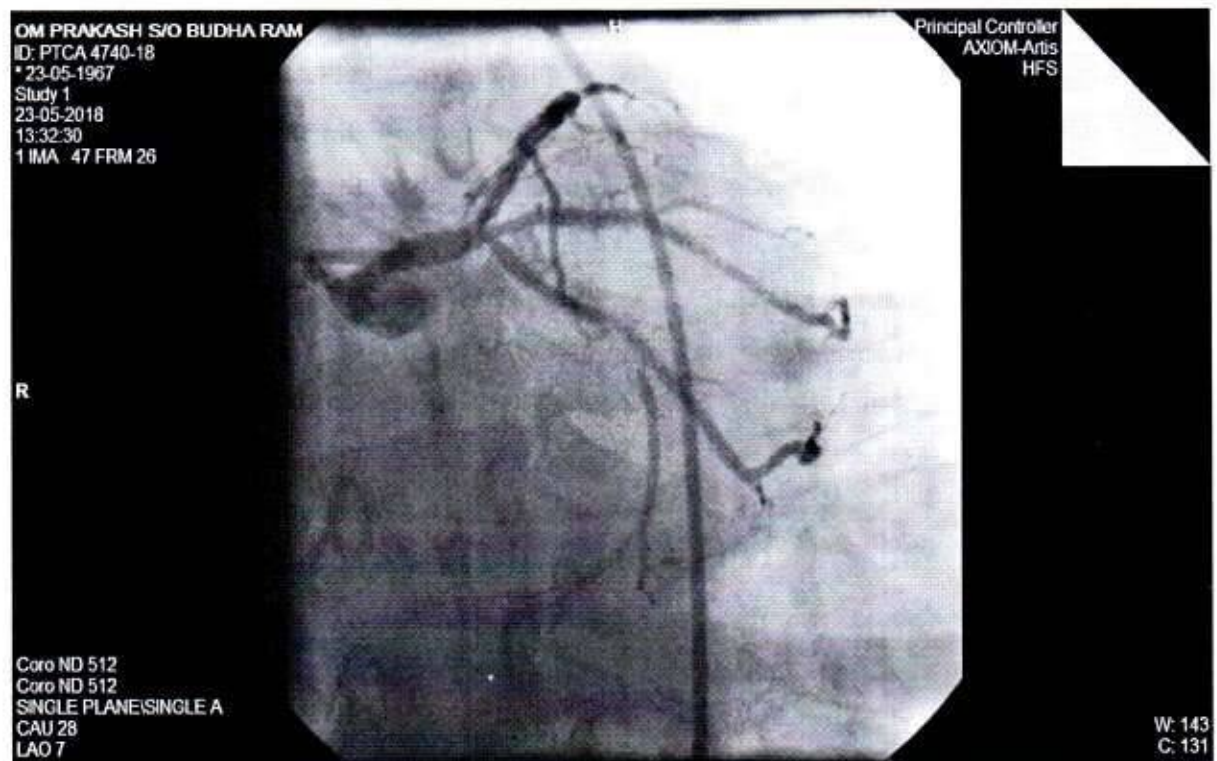


Fig 2: CAG post PTCA to Ramus intermedius

DISCUSSION

Cardiac cephalgia also known as angina capitis, angina cranialis, or simply as “headache angina”, is a rare condition reported to be around 6% by Sampson et al in 1971.[2] According to the International Classification of Headache Disorders (ICHD), 3rd edition, a diagnostic criteria has been proposed. [3] Cardiac cephalgia is suggested by the presence of at least two of the following:

1. Headache developed in temporal relation to onset of acute myocardial ischemia;
2. Headache worsened with worsening of the myocardial ischemia or headache improvement with improvement in the myocardial ischemia;
3. At least two of the following four characteristics:
 - a. Moderate to severe intensity,
 - b. Accompanied by nausea,
 - c. Not accompanied by photophobia or phonophobia, and
 - d. Aggravated by exertion; and
4. Headache is relieved by nitroglycerine or its derivatives.

Four theories have been postulated to understand the pathophysiology of cardiac cephalgia:

- a. Convergence theory: which says that afferent somatic and visceral fibers converge on the same neurons, and stimulation of visceral afferents causes relay of information corresponding to somatic region [4].

- b. increase in intracranial pressure [5].

- c. Cardiac ischemia causes release of neuromediators—serotonin, bradykinin, histamine, substance P, ANF (atrial natriuretic factor), which result in vasodilatation of the cerebral vessels and cause pain.[6]

- d. concurrent constriction of both cardiac and the cerebral vessels [7].

Our patient met the diagnostic criteria of cardiac cephalgia. He had exertional headache which was relieved by sublingual nitrate and experienced relief in his symptoms post revascularization. His stay in the hospital post revascularization was uneventful and was discharged without any complication Cardiac cephalgia is a rare form of exertional headache. It is important to have the knowledge of this condition as early diagnosis may prevent any catastrophe. It should be especially suspected in elderly patients with underlying cardiovascular risk factors and presenting with exertional headache.

REFERENCES:

1. Lipton RB, Lowenkopf T, Bajwa ZH, Leckie RS, Ribeiro S, Newman LC, et al. Cardiac cephalgia: a treatable form of exertional headache. *Neurology*. 1997;49:813-6.
2. John J. Sampson, Melvin D. Cheitlin. Pathophysiology and differential diagnosis of cardiac pain. *Progress in Cardiovascular Diseases*. Volume 13, Issue 6, March 1971; 507-531.
3. Headache Classification Committee of the International Headache Society (IHS), The International Classification of Headache Disorders, 3rd edition (beta version). *Cephalalgia*, 33 (2013), 629-808.
4. P. Sathirapanya. Anginal cephalgia: a serious form of exertional headache. *Cephalalgia Int J Headache*, 24 (2004), 231-234.
5. R.B. Lipton, T. Lowenkopf, Z.H. Bajwa, R.S. Leckie, S. Ribeiro, L.C. Newman, et al. Cardiac cephalgia: a treatable form of exertional headache. *Neurology*, 49 (1997), 813-816.
6. J.A.K. Petersen, F.E. Nielsen. Headache: a rare manifestation of angina pectoris. *Ugeskr Laeger*, 164 (2002), 2515-2516.
7. P. McCrory. Recognizing exercise-related headache. *Phys Sportsmed*, 25 (1997), 33-43.